

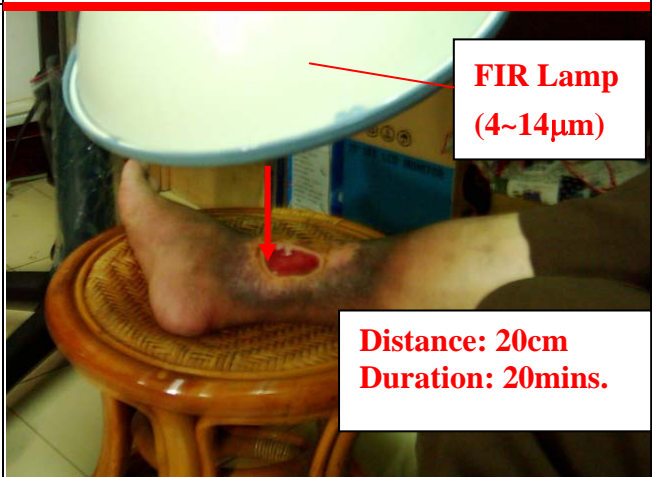

Curative Case of Far Infrared Ray on Stasis Dermatitis

Gender: Female | **Age:** 68 | **Treatment Duration:** 2004, Feb.18 to 2004, Apr.02


Medical Organization: BO TAI Dermatology Hospital, by Dr. CHANG ZHAO JIE

Stasis Dermatitis is a skin disease that often occurs on the lower extremities of elder patients. The cause is considered to be venous insufficiency in which defective valvular tissues from the venous system impedes flow of blood back to the heart and results in poor circulation in the lower limb. Stasis dermatitis is usually the earliest cutaneous sequela of venous insufficiency. This results in chronic eczema near inner ankle of the lower calf. And it may lead to more problematic conditions, such as ulceration, pigmentation, swelling, purpura and withered scars. The case is a 68-year-old female patient suffered from Stasis Dermatitis for over one year with an ulcerative wound that could not heal.


The Doctors from other hospital decide to treat this case by transplanting the skin of other region to repair the ulcerative wound. However, Dr. CHANG ZHAO JIE from Bo Tai Dermatology Hospital diagnosed the symptom and worked out a solution that tackled the cause: the insufficiency of microcirculation around the cells causes this skin disease and decreases cell regeneration. He employed energy of far infrared ray and shows impressive improvement in blood circulation and cells reproduction. He successfully treated the patient with **Far Infrared (FIR)** energy thereby avoided the transplanting method considered by other doctors.

| Date | Treatment | Wound Size | Photos |
|-------------------|--|------------|--|
| Feb.18~ Feb.21 | Internal Use: DACOCILIN、LIJEX External Use: Cleaning of wound with normal saline, 0.9% and iodine first. Followed by irradiation of Far Infrared (FIR) for 20 minutes at a distance of 20~25 cm. | 7 × 4 cm |  |
| Feb.22~ Feb.25 | Internal Use: External Use: Cleaning of wound with normal saline, 0.9% and iodine first. Followed by irradiation of FIR for 20 minutes at a distance of 20~25 cm. | 7 × 4 cm |  |


6 days after Feb.18, some changes took place around the wound; the skin around the wound started to grow.




| | | | |
|------------------|--|----------|--|
| Feb.26~ Ma.09 | <p>Internal Use:</p> <p>External Use: Clean wound with normal saline, 0.9% and iodine first.</p> <p>Followed by irradiation of FIR for 20 minutes at a distance of 20~25 cm.</p> | 5 × 3 cm |  |
|------------------|--|----------|--|

From Feb. 26 to Mar. 9, the wound healed gradually reducing from 7 × 4 cm to 5 × 3 cm in 11 days.

| | | | |
|-------------------|--|----------|---|
| Mar.10~ Mar.13 | <p>Internal Use: DACOCILIN、LIJEX</p> <p>External Use: Cleaning of wound with normal saline, 0.9% and iodine first.</p> <p>Followed by irradiation of FIR for 20 minutes at a distance of 20~25 cm.</p> | 3 × 2 cm |  |
|-------------------|--|----------|---|

From Mar. 10 to Mar. 13, the wound healed further reducing to 3 × 2 cm in 4 days.

| | | | |
|-------------------|--|----------|--|
| Mar.14~ Mar.15 | <p>Internal Use:</p> <p>External Use: Cleaning of wound with normal saline, 0.9% and iodine first.</p> <p>Followed by irradiation of FIR for 20 minutes at a distance of 20~25 cm.</p> | 3 × 2 cm |  |
|-------------------|--|----------|--|

| | | | |
|-------------------|---|--------------|--|
| Mar.16~ Mar.18 | <p>Internal Use:</p> <p>External Use: To clean the wound with normal saline, 0.9% and iodine first.</p> <p>Followed by irradiation of FIR for 20 minutes at a distance of 20~25 cm.</p> | 2 × 2 cm |  |
| Mar.19~ Mar.31 | <p>Internal Use:</p> <p>External Use: Cleaning of wound with normal saline, 0.9% and iodine first.</p> <p>Followed by irradiation of FIR for 20 minutes at a distance of 20~25 cm.</p> | 2 × 1.5 cm |  |
| Apr.01~ Apr.02 | <p>Internal Use:</p> <p>External Use: Cleaning of wound with normal saline, 0.9% and iodine first.</p> <p>Followed by irradiation of FIR for 20 minutes at a distance of 20~25 cm.</p> | 0.5 × 0.5 cm | <p>In 7 weeks, the wound almost completely healed and covered with newborn skin due to reproduction of skin cells.</p>  |

Conclusion:

The above-mentioned case study had been treated with the usual treatment for more than a year in other hospital without any improvement. Through general medication and a daily irradiation of far infrared ray for 20 minutes as supplementary therapy in this hospital, the wound healed completely. The therapeutic effect of FIR on wound healing is obvious and remarkable. The healing duration experienced in the case is also consistent with the common understanding that life cycle (period from cell reproduction to the next reproduction) of skin cells take approximately 28 days.